**PATIENT**

Leo Brewer

SPECIES

Feline

BREED

DLH

SEX

MN

AGE

2 years

WEIGHT

5.3 kg

INTERPRETED BYRemo Lobetti, BVSc,
MMedVet (Med), PhD, Dipl.
ECVIM**IMAGING PERFORMED BY**

Tom McNeill

HOSPITAL NAME

SVS Imaging CT

REFERRING VET

WVRC – Dr Vuolo

INVOICE

303483

DATE

10/15/22

PRESENTING CLINICAL SIGNS

History: 1-month duration progressive pain, inappropriate urination, and lethargy.

Physical Examination: Hyperesthesia mid-thoracic spine.

Urinalysis: N/A.

CBC: Non-diagnostic – clotted.

Serum Biochemistry: Fluctuating hypercalcemia.

Radiographic Findings: N/A.

ULTRASONOGRAPHIC EXAMINATION OF THE ABDOMEN**Urinary System**

Full urinary bladder with a normal thickness and appearance of the wall. Normal anechoic urine with no sediment or uroliths evident.

Normal trigone area, proximal urethra, and iliac blood vessels.

Normal iliac lymph nodes. Ureters not visualized.

Enlarged renal size (left 3.9 cm, right 4 cm) with increased echogenic appearance, some loss of cortico-medullary differentiation, and normal pelvis and capsule. Bilateral corticomedullary rim sign.

Reproductive System

N/A.

Adrenal Glands

Normal shape, echogenic appearance, position, and size. Left 0.32 cm, right 0.33 cm.

Spleen

Normal size (0.9 cm) and echogenic appearance. Smooth homogenous parenchyma, regular curvilinear capsule, and normal vasculature. No evidence of inflammatory, neoplastic, infarction, or infiltrative changes noted.

Liver

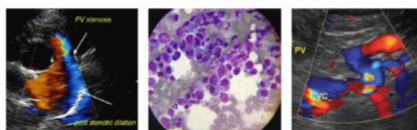
Normal size, echogenic appearance, portal markings, and regular curvilinear capsule. No nodules or masses evident. Full gall bladder containing normal anechoic bile. Normal appearance and thickness of the gall bladder wall. Normal bile duct.

Gastrointestinal

Normal appearance of the stomach, duodenum, small intestine, ileo-cecal junction, and colon with no loss of layering, normal wall thickness (stomach 0.18 cm, duodenum 0.26 cm, jejunum 0.17 cm, colon 0.1 cm) and peristaltic activity, and no distension of the lumen.

IMAGING PERFORMED BY

SVS Mobile Imaging CT 262-366-5970
fredgromalak@gmail.com



Clinical Sonography & Telectology

EDUCATIONAL TELECONSULTATION SERVICES™

1-800-838-4268 info@sonopath.com SonoPath.com

PATIENT *Pancreas*

Leo Brewer Normal size (left 0.9 cm) and echogenic appearance. Normal echogenic appearance of the mesentery and fat surrounding the pancreas.

SPECIES *Free Abdomen*

Feline Prominent mesenteric (0.4 x 1.8 cm), gastric (0.4 x 0.7 cm) and ileocecal (0.4 x 1.5 cm) lymph nodes with normal shape and hypoechogenic appearance.

BREED Small amount of ascites.

DLH

ULTRASONOGRAPHIC FINDINGS

SEX Primary Findings:

- Renal disease.
- Lymphadenomegaly.

AGE

2 years

Secondary Findings:

- Ascites.

WEIGHT

5.3 kg

INTERPRETATION OF THE FINDINGS & FURTHER RECOMMENDATIONS

Etiologies for the renal disease would be hypercalcemic nephropathy, FIP, lymphoma, and bacterial nephritis.

Etiologies for the lymph nodes would be reactive, lymphadenitis, and emerging lymphoma.

Further assessment would be urinalysis, urine culture, PTH assay, and FNA cytology of the kidneys and lymph nodes.

Specific therapy would be dependent on an etiological diagnosis.

INTERPRETED BY

Remo Lobetti, BVSc,
MMedVet (Med), PhD, Dipl.
ECVIM

IMAGING PERFORMED BY

Tom McNeill

HOSPITAL NAME

SVS Imaging CT

REFERRING VET

WVRC – Dr Vuolo

INVOICE

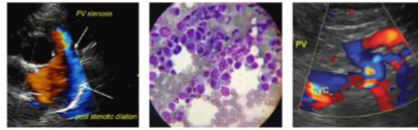
303483

DATE

10/15/22

IMAGING PERFORMED BY

SVS Mobile Imaging CT 262-366-5970
fredgromalak@gmail.com



Clinical Sonography & Telectology

EDUCATIONAL TELECONSULTATION SERVICES™

1-800-838-4268 info@sonopath.com SonoPath.com

PATIENT

Leo Brewer

SPECIES

Feline

BREED

DLH

SEX

MIN

AGE

2 years

WEIGHT

5.3 kg

INTERPRETED BY

Remo Lobetti, BVSc,
MMedVet (Med), PhD, Dipl.
ECVIM

IMAGING PERFORMED BY

Tom McNeill

HOSPITAL NAME

SVS Imaging CT

REFERRING VET

WVRC – Dr Vuolo

INVOICE

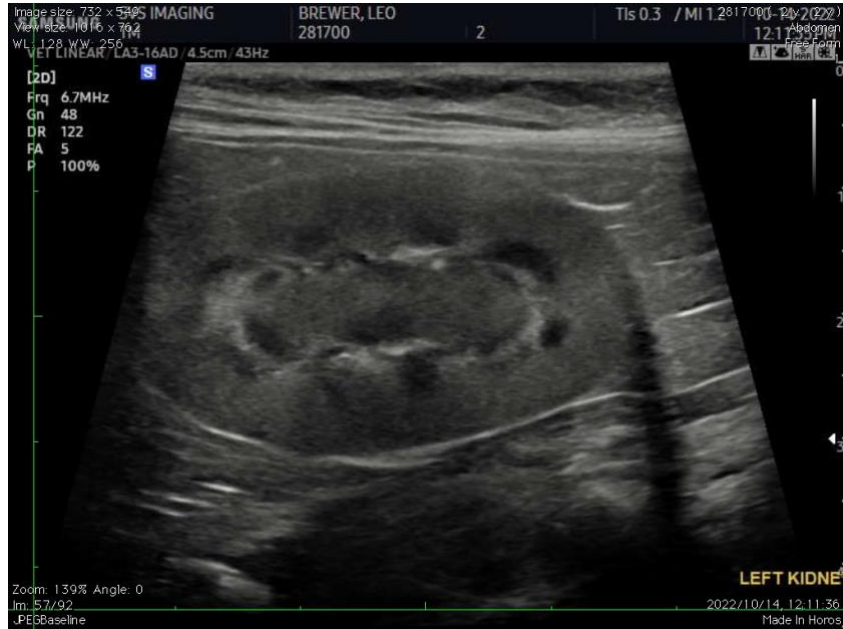303483

DATE

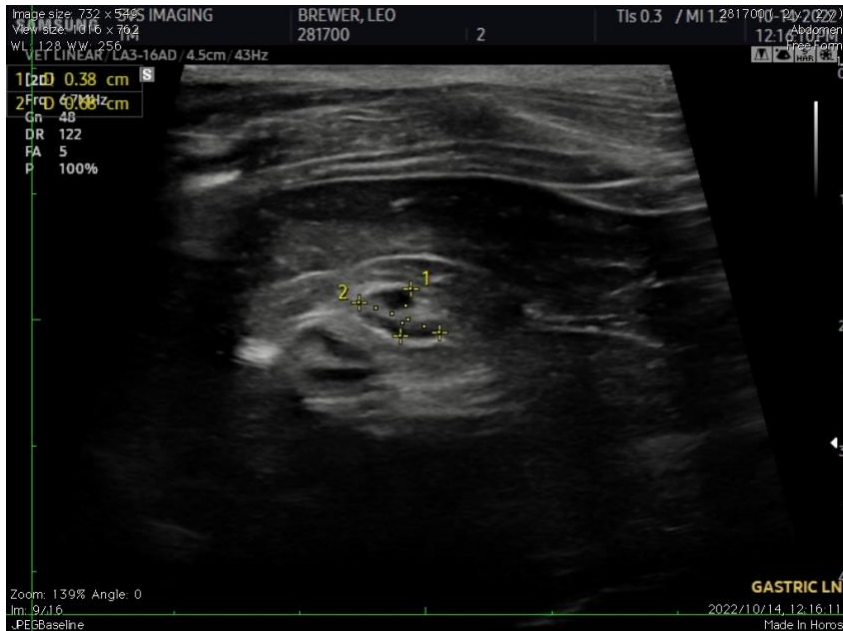10/15/22

IMAGES

Left kidney

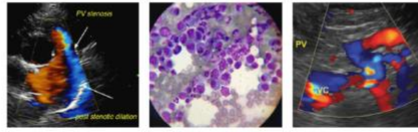


Gastric lymph nodes



IMAGING PERFORMED BY

SVS Mobile Imaging CT 262-366-5970
fredgromalak@gmail.com



Clinical Sonography & Telectology

EDUCATIONAL TELECONSULTATION SERVICES™

1-800-838-4268 info@sonopath.com SonoPath.com

PATIENT

Ileo-cecal lymph node

Leo Brewer

SPECIES

Feline

BREED

DLH

SEX

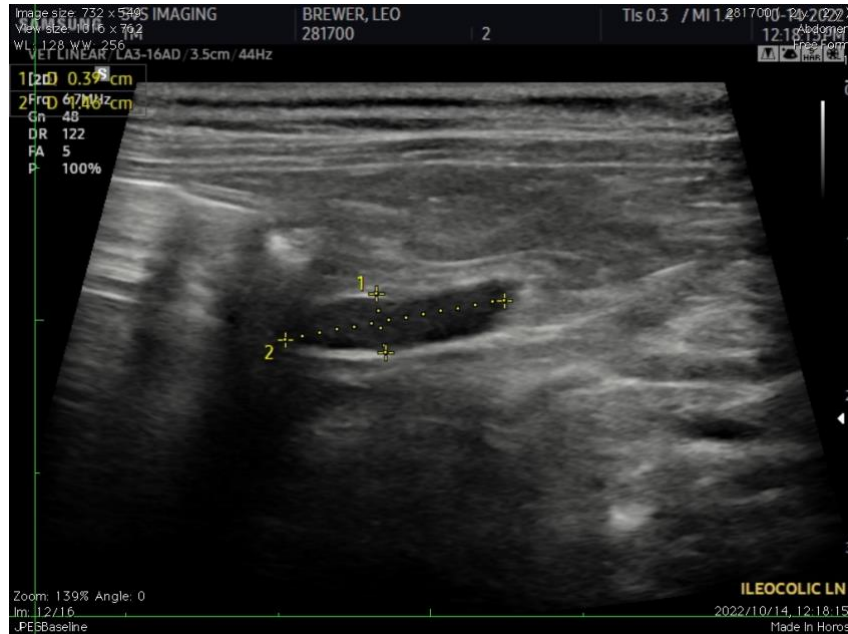MN

AGE

2 years

WEIGHT

5.3 kg



INTERPRETED BY

Remo Lobetti, BVSc, MMedVet (Med), PhD, Dipl. ECVIM

The information and recommendations provided are based on the images presented by the referring veterinarian. No evaluation can be communicated regarding pathology that was not visible in the image/video clips provided.

Thank you for this referral. If the clinical or image interpretation does not parallel your findings or if I can be of any further assistance, please contact me.

Remo Lobetti, BVSc, MMedVet (Med), PhD, Dipl. ECVIM (Internal Medicine)
rlobetti@mweb.co.za

IMAGING PERFORMED BY

Tom McNeill

HOSPITAL NAME

SVS Imaging CT

REFERRING VET

WVRC – Dr Vuolo

INVOICE

303483

DATE

10/15/22